

## mighty mites:

# CHORIOPTIC SKIN DISEASE IN alpacas

By Dr. Ed McCaslin, DVM

*Skin disease in alpacas can be due to a variety of different causes: bacteria, fungi, allergies, nutritional problems, and various parasites. One of these parasites is the Chorioptic mange mite.*

*Chorioptic mange can be a real headache to the alpaca owner. Difficult to diagnose and even more difficult to treat, this exasperating parasite can masquerade as its cousin, Sarcoptic mange, or hide out under secondary fungal and/or bacterial infections. Symptoms can be quite variable from one animal to the next, further confusing the situation.*

*The economic impact of Chorioptic mange due to loss of usable fiber, loss of animal sales, and cost of treatment is hard to estimate, but it certainly is substantial. This does not take into account the discomfort to the animals and the general unthriftness it creates.*

*Alpacas are susceptible to at least four different types of mange mites. Unfortunately, the three most common kinds – Sarcoptes, Chorioptes, and Psoroptes – look very much alike under the microscope. Many times, a vet will give a quick glance, see mites, and assume they are Sarcoptes, long thought to be the most common kind in alpacas. Based on the cases I am now seeing, however, I believe Chorioptes has become the most common type, at least in Ohio and surrounding states.*

## the journey

My story started in 2007, with an alpaca that had been treated unsuccessfully for Sarcoptic mange over a two-year period. Repeated skin scrapings were always negative for mites, and yet the symptoms were there. The herd-mates all seemed pretty normal, though eventually a couple of them showed a bit of a scaly area between the toes. A skin scraping from the toe area revealed a single mite. As I studied the mite under the microscope, it did not look exactly like a Sarcoptes mite. I consulted textbooks and came to the conclusion that it must be Chorioptes. I sent the slide out to a parasitologist, who confirmed my suspicion that it was indeed Chorioptes bovis. Chorioptic mange can affect horses, cows, and (rarely) sheep and goats, as well as alpacas. Unlike Sarcoptic mange, it does not affect humans.

Well, now I had a diagnosis. I just needed an effective treatment. I consulted with various camelid experts, parasitologists, and a veterinary dermatologist. The consensus was “This stuff is really hard to treat.” Nothing seemed to work very well. Injectable ivermectin sometimes reduced the number of mites, but never completely eliminated them. The various “Witch’s Brew” mixtures were often useful in the short term, especially when there were secondary infections present, but the lesions almost always came back eventually. Pour on treatments such as Eprinex® and Frontline Plus®

had also been tried without much success. One clinician mentioned lime sulfur dip. I had used lime sulfur dip years ago on kittens. It was smelly and messy and a lot of work. The idea of using it on a whole herd of alpacas was not appealing, so I kept it in the back of my head as a last resort and kept looking.

A veterinarian from Merial Technical Services found some articles that had been published in the UK concerning the use of fipronil on Chorioptic mange in horses and camelids. I decided to try it and it worked very well. As time went on, I saw other animals at other farms with similar symptoms. Diligent skin scrapings turned up Chorioptic mites in these animals also. Once again, we found it was much easier to recover the mites from the healthy herd mates than from the obviously symptomatic animal. This was consistent with the findings described in the British literature. Fipronil worked well on these animals also.

The folks at Merial Technical Services have been very helpful to us. Because the British literature provided a dosage, but not a treatment protocol, they provided me with enough Frontline® Spray to work out the optimum frequency and duration of treatment in our own herd. Doing skin scrapings on every animal in the herd every month was “character building,” but I was able to determine that treating every three weeks for a total of four treatments was the most effective plan.

## symptoms

This condition often presents as a somewhat “itchy” animal with spotty hair loss, usually around the feet and lower leg region, but it can occur on other areas of the body, as well. The foot lesions may be partially hidden by the fleece and may not be terribly obvious from a distance (*fig. 1*), but are quickly apparent when you lift the foot and separate the toes (*fig. 2*). In longstanding cases, the tissues can thicken, causing the toes to splay. (*fig. 5*) The most common sites, other than the feet, are the axillary (armpit) and inguinal (groin) regions, the perineal (genital) region, and the ventral tail area, but all parts of the body can on occasion be involved.

Most of the animals show rather mild symptoms and owners may be unaware that there is anything wrong. A small percentage of animals (only one or two per farm) are more severely affected with easily visible lesions and hair loss. This is why many people will think “It can’t be mites because only one animal on the farm is affected.” This was also consistent with the British literature. The British authors posit that this is a hypersensitivity, and I concur.

Some of these more severely-affected animals will develop secondary bacterial and/or fungal infections. These secondary infections are more common under humid conditions and less common during dry times.

This disease does not appear to run in family lines. Overcrowding as can occur through the winter may contribute to this being spread more rapidly through a herd.

## Life cycle

Unlike Sarcoptic and Psoroptic mange mites, which burrow deep into the epidermis (*see fig. 7*), the chorioptic mite normally lives its entire three-week life cycle on the surface of the skin. The favored location for Chorioptic mange mites is the dorsal skin of the area between the toes. Chorioptic mites feed on dead skin cells and dander. The female can lay up to 90 eggs during its life. Because it is a superficial mite, Chorioptes can be easily dislodged into the environment, where it has been reported that the adult mite can survive up to 70 days off the host in the environment. (One hardy specimen from our study even survived for 11 days completely immersed in mineral oil and under a glass cover slip!)

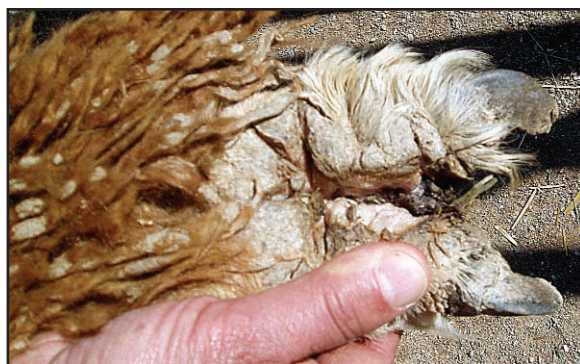Unlike the sarcoptic mange mites, the chorioptic mites are not contagious to humans but will spread easily to other alpacas and even other livestock like cattle, horses, sheep, and goats. Fomites – physical objects like toe nail trimmers, grooming tools, halters, bedding, shearing equipment, and the ground itself – can harbor live mites that then spread to the next animal.

We tried to find a product that would eliminate the mites from the environment. We found that 99% alcohol will kill the mites on shearing equipment and other fomites. Fipronil will do the same. However, we could not find anything that was safe, effective, and economically feasible for barn floors and paddocks, etc.

As I studied the life cycle of



**Figure 1** Affected foot, standing.



**Figure 2** Same foot, toes spread.

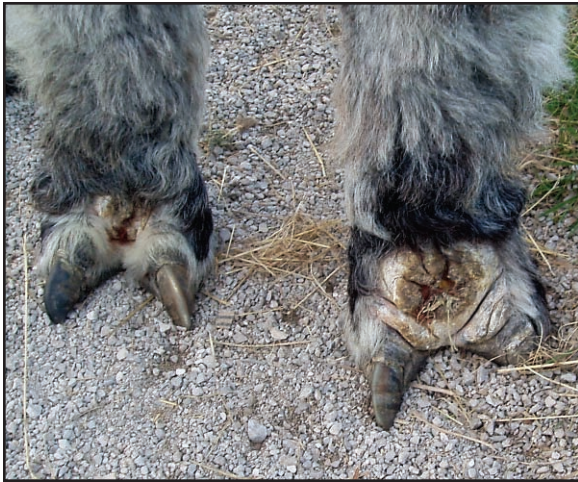

**Figure 3** Same foot, one month post-treatment, hair starting to regrow.



**Figure 4** Same foot, 9 months post treatment.

Photos © 2009 Drs. Ed and Ruthanne McCaslin



**Figure 5**  
Chronic case  
with thickened  
tissues and  
splayed toes.



**Figure 6** Lesions  
on upper legs  
and body.

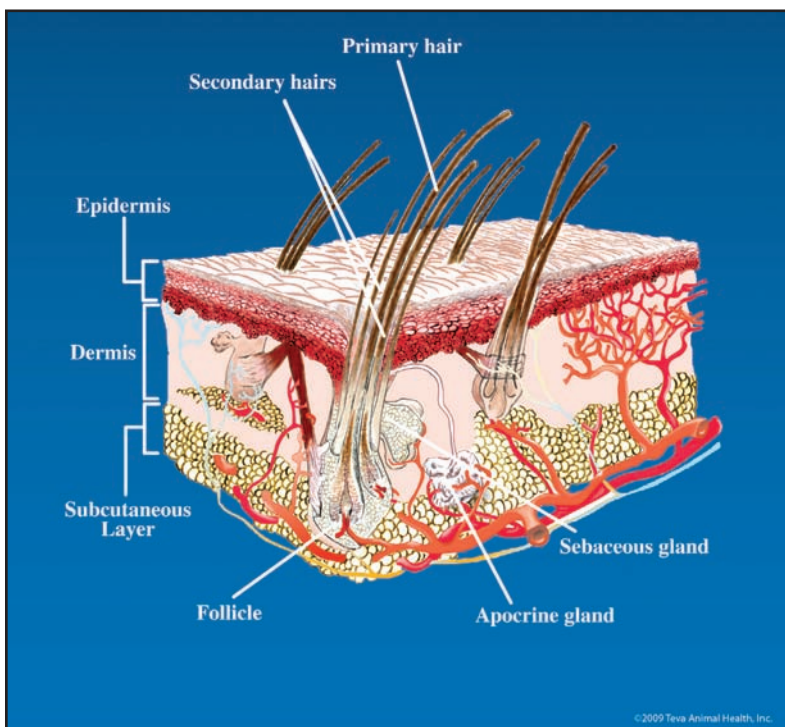
the Chorioptic mites, it became apparent why some of the previous treatments had not worked. Injectable ivermectin works extremely well against *Sarcoptes* and *Psoroptes*, which it can reach through the blood vessels in the epidermis, but is much less effective against *Chorioptes* which stays on the surface, where the injectable drug does not penetrate well.

Eprinex® and Frontline Plus® are applied along the top of the back and depend on translocation via the lipid layer on the surface of the skin to spread over the body surface. Since the alpaca has almost no lipid layer, it is not surprising that these products failed to spread from the top of the back all the way down to the feet, where the majority of the *Chorioptic* mites are found.


## DIAGNOSIS

Alpacas are susceptible to at least four different types of mange mites. Unfortunately, the three most common types – *Chorioptic*, *Sarcoptic*, and *Psoroptic* – will at first glance under a microscope look remarkably similar, but the treatments are very different. Even many veterinarians will confuse the three if they are not familiar with the subtle differences. It is critical for your veterinarian to be able to identify the subtle structural differences in the mites to make the correct diagnosis and treatment recommendations.

Skin scrapings are done using a #10 scalpel blade (held between thumb and finger – not on a handle) and mineral oil. It is important to scrape firmly and gently until you begin to see capillary bleeding. This insures that you have gone deep enough not to miss any *Sarcoptic* mites that are burrowed



**Figure 7** Cross Section of Mammalian Skin.



**Figure 8** Dr. Ed obtaining a skin scraping.

into the epidermis. Multiple scrapings are generally needed.

I can usually get good skin scrapings from the body surfaces or the feet without sedation. For severe cases where the animal is in pain or to collect samples from the face and ears (*figs. 9 and 10*), some sedation may be prudent. I prefer to take my time and get a good sample than to rush and miss a diagnosis. Be sure to have your veterinarian get samples from some of the healthy-looking animals housed with the obviously affected animal. The mites are much more numerous and easier to find on them.

Once the sample is on the microscope slide and the mites are “trapped” under a cover slip, start at 40x magnification and look for movement. The mites are quite active at room temperature.

You must move up to the 100x magnification to identify the mite. The only visible differences are in the pedicel, the slender stalk that connects the small “suction cup” to the end of the leg (*fig. 14*). The pedicel of the chorioptic mite is short and unsegmented, the pedicel of the sarcoptic mite is long and unsegmented. The pedicel of the psoroptic mite is long and segmented. As you can imagine, it is not easy to focus on this tiny structure at the end of a tiny, rapidly-moving leg. At this point, it may be helpful to refrigerate the slide for a little while to slow down the activity of the mites. Be sure to identify multiple mites from each sample before making a final diagnosis. It is possible for a single animal to be carrying more than one kind of mite.

## STUDY DESIGN

The “Alpaca Grapevine” is marvelously efficient and when word got out that we had found an effective treatment, we began to get referrals from veterinarians and other alpaca farms from several surrounding states. Many folks were encouraging us to write about it, so we decided to do an informal study at our own expense. We asked each participating farm to bring the animal they perceived to have a problem and to also bring an animal they perceived to be healthy from the same pen or paddock. We took an oral history (asked questions about onset and duration of symptoms and other questions about husbandry, etc.) We carefully examined the skin on each animal from ear tip to toenail and from nose to tail. We did skin scrapings on both animals using a #10 scalpel blade and mineral oil. We scraped the area between the toes on the right front and right rear foot of each animal and, in addition, did scrapings from any other area that showed hair loss, scaling, thickening, or other changes. In a few of the more severely affected animals, we elected to do biopsies and cultures for bacteria and fungus.

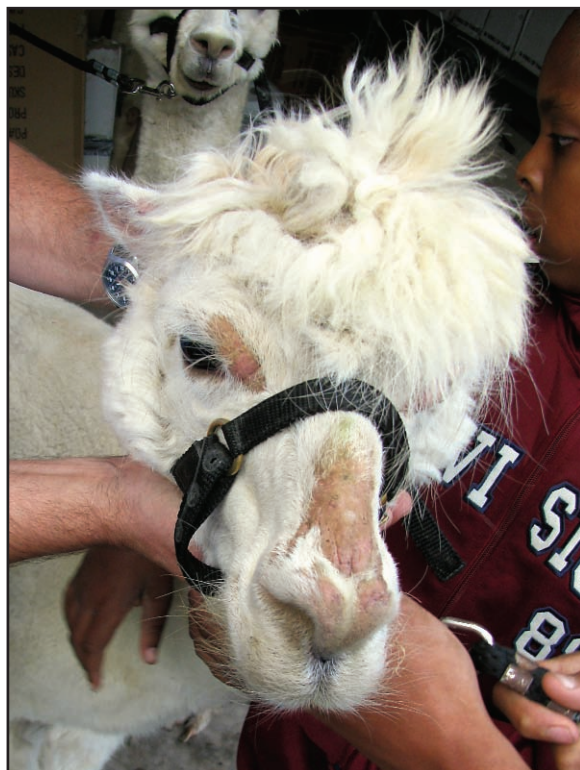

Figure 8 Lesions on nose and face.

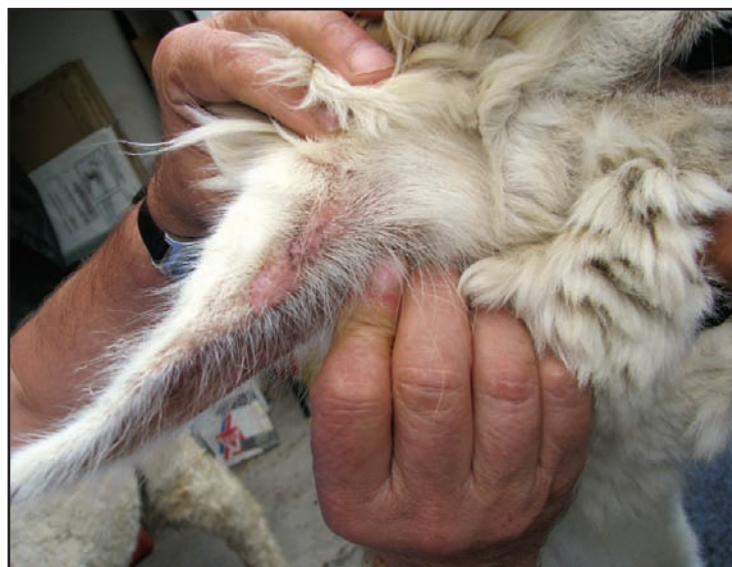

Figure 9 Lesions on ear.


Photos © 2009 Drs. Ed and Ruthanne McCaslin



**Figure 11** Adult male Chorioptic mite, 400x.



**Figure 12** Adult female Chorioptic mite, 400x. Shows location of the pedicel.



**Figure 13** Chorioptic mite showing very short, non-segmented pedicels.

Photos © 2009 Drs. Ed and Ruthanne McCaslin

## results

I have been able to find chorioptic mange mites in almost all of the 200+ animals that I have examined. I have found live mites on crias as young as two months of age and as old as 16 years. These animals came from more than 50 different farms in five Midwestern states. There were over 2,000 alpacas represented on these farms. Each of the farms that came to us did so because they had an animal with an obvious problem. Very few farms had more than one animal they were concerned about. Symptoms ranged from itching to a severe generalized hair loss with secondary infection (pyoderma) over large portions of the body.

Most of the “problem” animals had been under treatment for their skin problems using a variety of different products for weeks or months before we saw them. Several had been misdiagnosed as having “ivermectin-resistant Sarcopic mange.” No Sarcopic mites were found on any of them. Others had been diagnosed as fungal, allergic, and zinc deficient.

The interesting thing is that almost every “normal” animal that we saw had some symptoms of Chorioptic mange – much milder symptoms than the “problem” animal, but very evident to the trained eye, often without even bending over. The most frequent symptoms in these “normal” animals were scaly and thickened skin between the toes. The most severely affected animals consistently yielded the fewest mites on skin scrapings,

whereas “normal” animals housed with these “problem” ones consistently yielded much larger numbers of mites.

We tried doing Scotch tape preps on some of these animals. The Scotch tape is applied to the skin between the toes and then applied to a microscope slide. We had hoped to find a less invasive way to detect the mites and one that alpaca owners could collect without veterinary assistance and mail off easily for a diagnosis. It did work in some cases, but gave too many false negatives, plus it was very difficult with the Scotch tape preps to visualize the pedicels well enough to identify the mites reliably.

We were able to follow up at least in the short term with most of the participating farms and the results were overwhelmingly positive. We have only been able to follow up in the long term with a few of the participating farms, but those who followed the protocol have cleared all their mites and remain mite-free. The numbers we have right now are too small to draw sweeping conclusions, and it is likely that the farms participating in the follow-up were among the most compliant farms. Because we dealt only with farms that knew they had a problem of some sort, we cannot generalize these numbers to the overall population. It would be interesting to study animals from farms where all of the animals have healthy skin and see if those animals harbor any mites.

## treatment

I have had good success treating and controlling this condition with fipronil (Frontline® Spray) by Merial. Fipronil works by altering the function of the nervous system of invertebrates. It will kill the mites it contacts within two hours and will continue to work for up to one month. I have found that repeat treatment of affected and companion animals every three weeks, for a total of four treatments, gives the best results. (I initially tried treating once a month and found it inadequate.)

Frontline® Spray doesn't translocate (spread out to areas of the body that have not been sprayed), although a small amount may transfer to the axillary (armpit) and inguinal (groin) areas when the animal is cushed. It doesn't enter the body of mammals. It travels along the hair follicles and enters the sebaceous glands. It is stored in the sebaceous glands and gradually "wicks out" over the next 21-30 days.

Fipronil is safe to use on late-term pregnant animals and even nursing mothers, although I avoid applying it directly to the udder while a cria is still nursing. Fipronil is not harmful to humans or any other mammal, but does carry a warning for honey bees and fish.

The most effective way to use the fipronil is to apply it to all four feet from the fetlock joint down to the toenails covering the front, back, and sides of the feet. You should also treat all other visibly affected areas of the body. Especially look at the armpit, groin area, and perineal region

extending up to the underside of the tail. Application of the fipronil to the face, head, or other sensitive areas should be done carefully with a gauze pad soaked in the spray. I can generally treat 10 to 12 adult alpacas with each 500 ml bottle of the Frontline® Spray.

Concurrent use of antibiotics like Naxcel (Upjohn) may be needed if there is secondary infection. Your veterinarian can advise you as to whether other medications including topical antibiotics and/or antifungals would be helpful.

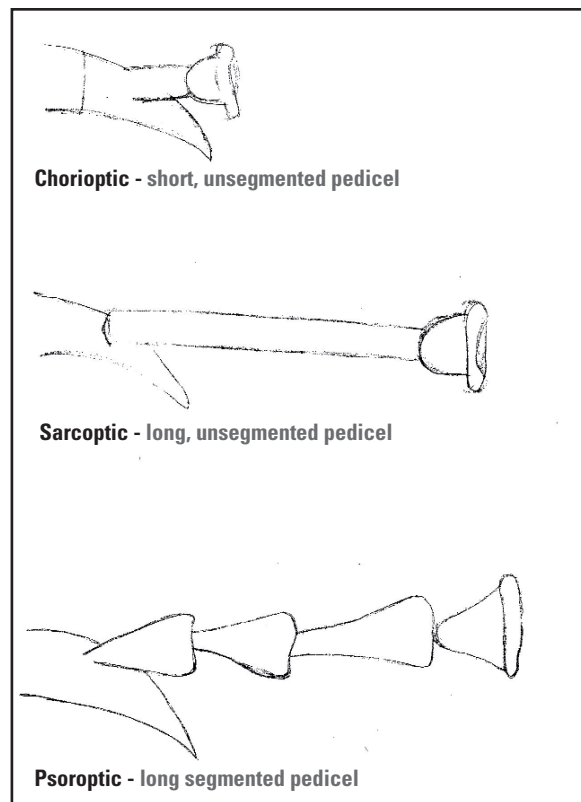


Figure 14 Differences between the pedicels of the various mites.

Diagram © 2009 Ali Felice

## RECOMMENDATIONS

If you suspect that you are dealing with Chorioptic mange in your herd, have your veterinarian do skin scrapings on as many of your animals as possible. Be sure to include some apparently healthy animals that are housed with the visibly affected animal(s). Also be sure your veterinarian is aware of the differences in the pedicel (see *Diagnosis*).

### To rid a farm of Chorioptic mange mites:

1. Treat all animals on the farm that are one month old or older with Frontline® Spray as directed every three weeks for at least four treatments.
2. Remove all organic material from the barn floor to the extent possible.
3. Randomly recheck 10% of herd by skin scrapings 1-2 months after the last treatment to be sure you have eliminated the problem.
4. Be very cautious about buying Frontline® Spray over the Internet. There are a number of companies out there selling counterfeit products.

### To keep a farm free of Chorioptic mange mites:

1. Do skin scrapings on all new animals brought to your farm.
2. Whether positive or negative, spray all feet on animals entering the farm or returning to the farm, including those returning from shows.
3. Don't share halters, leads, nail trimmers, or grooming or shearing equipment between animals without cleaning, disinfecting, or spraying with fipronil first.
4. Be careful about contact with other livestock such as cattle, sheep, goats, and horses.
5. Randomly recheck 10% of the herd by skin scrapings every six months.

## WRAP UP

I do believe we can conclude Chorioptic mange is much more prevalent than was previously believed. It also appears that fipronil can be a useful tool in controlling it. Some new work is also being done using topical lime-sulfur treatment. It, too, looks promising, but the whole Chorioptic mange mite syndrome needs a lot more study before we can say we have it completely understood or can offer a sure-fire "cure."

The work behind this study and this article is a task I could

never have accomplished alone. Patricia Nash has provided much technical support and enthusiasm and most of the photographs. Her daughter, Alexandra Felice, provided the detailed drawings of the pedicels. Mary Jane Fox patiently held many animals for multiple skin scrapings and also helped Patricia test disinfectants for the shearing equipment. Finally, without the help of my wife, Dr. Ruthanne, and the countless hours she has contributed to this project, it would never have been completed.

---

Dr. Ed McCaslin, affectionately known as "Dr. Ed," grew up on a chicken farm in rural Maine. He graduated from veterinary school at Michigan State University, where he met and married "Dr. Ruthanne." Together, they own the Lakeshore Animal Hospital in Mentor, Ohio. They also own Promised Land Farm in Chardon, Ohio where they have been raising alpacas (and Dr. Ed's pet chickens) since 1995. Dr. Ed has always had a special interest in dermatology and parasitology. He can be reached at [www.blackalpaca.com](http://www.blackalpaca.com) or [blackalpaca@hotmail.com](mailto:blackalpaca@hotmail.com).

## BIBLIOGRAPHY

1. Managing Parasites: Parasitic Skin Disease in South American Camelids, *Alpaca World*, Aiden P. Foster PhD, Dip ACVD, MRCVS, Veterinary Investigation Officer VLA, Shrewsbury, UK
2. Concurrent Sarcoptic and Chorioptic Acariasis in a British Llama, *Veterinary Record* 2001, 149, 208-209, C.F. Curtis, S. J. Chappell, R. Last
3. Efficacy of Topical Eprinomectin in the Treatment of Chorioptes sp. Infestation in Alpacas and Llamas, 10-10-06, Jon D. Plant, Michelle A. Kutzler, and Christopher K. Cebra
4. Prevalence of Chorioptes sp. Mite Infestation in Alpacas in the Southwest of England: Implications for Skin Health, *Small Ruminant Research*, Vol 57, Issues 2-3, March 2005G. L. D'Alterio, C. Callaghan, C. Just, A. Manner-Smith, A. P. Foster, and T. G. Knowles
5. Comparative Study of the Efficacy of Eprinomectin Versus Ivermectin, and Field Efficacy of Eprinomectin Only for the Treatment of Chorioptic Mange in Alpacas. *Veterinary Parasitology*, Vol 130, Issues 3-4, June 30, 2005 Pages 267-275 School of Clinical Veterinary Science, Univ of Bristol, Langford House, UK, G>L. D'Alterio, A. P. Jackson, T.G. Knowles, and A.P.Foster
6. Llama Dermatology, *Vet Clin North Am Food Animal Pract.*, 1989 Mar; 5(1): 203-15 Rosychuk, RA
7. Equine Chorioptic Mange: An Epidemiologic Study and Controlled Clinical Trial, British Veterinary Dermatology Study Group, Bristol UK, October 1999, Littlewood, J.D.
8. Control of Ectoparasites in Horses, *In Practice*, Sept 1999, Janet Littlewood, UK
9. Fipronil: NPTN, Oregon State Univ, EPA, Corvallis, Oregon, 1996
10. Epidemiological Investigations of Bovine Chorioptes Mange in Germany, *Berl Munch Tierarztl Wochenschr*, Mar-Apr 2005, 118 {3-4} 128-33, Beck W., Pfister K., Weiland G.
11. Comparative Study of Doramectin and Fipronil in the Treatment of Chorioptic Mange, *The Veterinary Record* {British Veterinary Association, 161:335-338 {2007}, D.I. Rendle BVSc, MRCVS, H.J. Cottle BVSc, MRCVS, S. Love, BVMS, PhD, MRCVS, K.J. Hughes BVSc, MRCVS
12. *Alpaca Field Manual*, 3rd edition, 285-322, C. Norman Evans, D.V.M.
13. *Medicine and Surgery of South American Camelids* {205-210, 250-259}, Murray E. Fowler, DVM
14. *Parasitology for Veterinarians* {54-61} Jay R. Georgi D.V.M., PhD.
15. *Helminths, Arthropods, and Protozoa of Domesticated Animals*, 6th Edition {512-513} E.J.L. Soulsby